

Use of porcine small intestinal submucosa for corneal reconstruction in dogs and cats: 106 cases

E. GOULLE

Clinique Veterinaire Aquivet - Service d'Ophthalmologie, Parc d'activités Mermoz Avenue de la Forêt Eysines 33320, France

OBJECTIVES: To describe the efficacy of porcine small intestinal submucosa in corneal reconstructive surgery in dogs and cats through a large retrospective study.

METHODS: A retrospective evaluation of 106 cases of surgical reconstruction of the cornea with small intestinal submucosa seen between May 2005 and January 2010 was carried out. The corneal defect was filled by microsurgical grafting of porcine small intestinal submucosa. The biomaterial implant was deposited in one or several layers depending on the depth of the defect. The animals were examined 3, 6 and 12 weeks after surgery.

RESULTS: Vision was preserved in all eyes at three months post-surgery. In 74 cases (69.8%) the corneal scar was either transparent or discrete, whilst in 32 cases (30.2%) a mild or marked scar was observed. Minor complications occurred in 9 cases (8.5%) with partial integration of the small intestinal submucosa and in 24 cases (22.6%) with faint or mild corneal pigmentation, without impairing vision. In cases followed over a period longer than three months, major complications occurred in five dogs resulting in vision impairment because of pronounced pigmentation.

CLINICAL SIGNIFICANCE: Corneal grafting of porcine small intestinal submucosa is an effective method for corneal reconstruction resulting in corneal transparency in most cases. It is an excellent alternative to conventional conjunctival grafts.

Journal of Small Animal Practice (2012) **53**, 34–43
DOI: 10.1111/j.1748-5827.2011.01149.x

Accepted: 25 September 2011; Published online: 28 November 2011

INTRODUCTION

A severe corneal defect in dogs and cats can be defined as the loss of more than half of the corneal thickness, until corneal perforation in the most severe cases. These corneal defects have a variety of aetiologies including traumatic, infectious or surgical (keratectomy). Several surgical grafting techniques have been described for replacement of the lost corneal substance including lamellar corneal graft, penetrating keratoplasty, corneoscleral transposition, conjunctival graft (island, bulbar pedicle, tarsconjunctival, bridge, advancement or complete bulbar graft) (Hakanson and Merideth 1987, Gelatt and Gelatt 1995, Hendrix 2007), as well as synthetic grafts (Wilkie and Dan Wolf 1991) and biomaterial grafts. Corneal graft surgery has proven efficacy (Hansen and Guandalini 1999), but the difficulty of obtaining corneal transplants (fresh or frozen) limits the availability of this option

in veterinary surgery. The use of different biomaterials including amniotic membrane, renal capsule and equine pericardium for corneal reconstruction surgery in the dog and horse has been reported. However, these transplant materials can be difficult to obtain (Barros and others 1995, 1997, 1998, 2005, Andrade and others 1999, Lassaline and others 2005, Ollivier and others 2006). Small intestinal submucosa (SIS) is an alternative biomaterial that is easier to procure and preserve. It has been used extensively in veterinary ophthalmology (Lewin 1999, Featherstone and Sansom 2000, 2004, Featherstone and others 2001, Bussieres and others 2004, Vanore and others 2007). SIS is a non-immunogenic biomaterial capable of acting as a scaffold for tissue regeneration in different organs (Featherstone and Sansom 2000) including the eye (Lewin 1999, Featherstone and Sansom 2000, Featherstone and others 2001, Bussieres and others 2004, Vanore and others 2007). Its use has previously been described in surgery to repair the fascia lata (Dejardin and others 1999), the

skull (Cobb and others 1999), loss of arterial substance (Badylak and others 1989) and for intra-articular grafts of the cruciate ligament (Aiken and others 1994). This biomaterial is composed of an acellular collagen matrix that acts as a medium for corneal remodelling and reconstruction (Lewin 1999, Featherstone and Sansom 2000, Bussieres and others 2004, Vanore and others 2007). A study in the rabbit showed that the grafted material merges with the corneal stroma in the healing process (Griguer and others 2001). The biocompatible protein matrix is initially invaded by fibroblasts which are then replaced by corneal stromal cells (Vanore and others 2007). In previous reports, SIS was used with a good outcome in the management of canine and feline corneal diseases (Lewin 1999, Featherstone and Sansom 2000, Featherstone and others 2001, Bussieres and others 2004, Vanore and others 2007). SIS was used in conjunction with a conjunctival graft to repair a full-thickness corneoscleral defect resulting from the excision of a limbal melanoma in a German shepherd dog, with a good incorporation of the graft into the cornea and sclera (Lewin 1999). In another report, two cases of feline ulcerative keratitis were treated with SIS, resulting in a good outcome (Featherstone and Sansom 2000). In a study of 10 cases of feline corneal disease, eight eyes healed with minimal corneal scarring and with a very good cosmetic and visual result. One eye required a conjunctival pedicle graft whilst one required enucleation (Featherstone and others 2001). Another article reported the use of SIS graft covered by a conjunctival flap for the repair of full-thickness corneal wounds in dogs, cats and horses (Bussieres and others 2004). In their series, despite post-operative complications (aqueous leakage, conjunctival flap dehiscence, synechia, fibrin and cataract), 14 of the 15 cases were visual at the final re-evaluation. Finally, SIS grafts were used for the surgical repair of deep melting ulcers in five dogs and two cats. All eyes healed without complications and retained corneal transparency, even in the presence of corneal perforation in two cases (Vanore and others 2007).

This large retrospective study describes treatment of 106 eyes in 102 animals (60 dogs and 42 cats) by surgical reconstruction of the cornea with SIS between May 2005 and January 2010.

MATERIALS AND METHODS

This retrospective study includes 60 dogs and 42 cats (106 eyes) that underwent a microsurgical graft of SIS for reconstruction of corneas with severe corneal defects from May 2005 to January 2010.

Ophthalmologic examination

A thorough ophthalmologic examination was performed in each case, with bilateral evaluation of the menace response, palpebral reflex, dazzle reflex and pupillary light reflex. Schirmer tear test (Standardized Sterile Strips, Schering-Plough Animal Health Corp) and fluorescein test (Fluoresceine 0.5% collyre unidose, TVM) were performed. All corneas were examined by slit-lamp biomicroscopy (Hawk Eye, Dioptrix), before and after fluorescein testing (except in cases of corneal perforation), for accurate

evaluation of the depth of the corneal lesion to be filled, except in the cases of surgically induced defects (deep keratectomy). In these cases, evaluation was performed during surgery under the operating microscope. All cases in this study displayed a severe corneal defect, i.e. the loss of more than the half of corneal thickness, with a descemetocoele or corneal perforation resulting in some cases. Applanation tonometry (Tono-Pen Vet, Reichert) was performed in all cases, except for those with collapse of the anterior chamber because of corneal perforation.

Surgery

In every case, surgery was performed using an operating microscope (Variflex, Möller-Wedel). General anaesthesia was induced by intravenous injection of 5 mg/kg tiletamine-zolazepam (Zoletil, Virbac). Pain management was by subcutaneous injection of 4 mg/kg carprofen (Rimadyl, Pfizer) or by intramuscular injection of 0.25 mg/kg morphine (Morphine 10 mg, Lavoisier). After endotracheal intubation, anaesthesia was then maintained with isoflurane (Isoflurane Belamont, Nicholas Piramal Limited) and oxygen. Marbofloxacin (Marbocyl FD, Vetoquinol) was injected intravenously at a dose of 2 mg/kg. As recommended for all ophthalmic surgical procedures, careful disinfection of the periocular region and the globe was performed with a mild antiseptic solution of povidone-iodine (diluted at 1% for the eyelids and 0.2% for the cornea) (Gelatt and Gelatt 2003).

The cornea was surgically prepared before SIS grafting by excising all malacic tissues using a beaver blade. SIS was available in the form of fine sterile rectangular sheets (10 cm×7 cm) or circular discs (10 to 15 mm in diameter), with a smooth side and a rough side, and a thickness of about 100 µm (Vet Biosist, SurgiVet Veterinary Products, Smiths Medical Pm Inc). The rough side was the tunica muscularis mucosal surface whilst the smooth surface was the stratum compactum surface of the tunica mucosa (Bussieres and others 2004). Only rectangular sheets were used in this series. For each case, the transplant was cut from the sheet, either with a trephine, if the corneal defect was circular, or with micro-scissors if the shape of the defect was irregular. The transplant was then systematically examined under the operating microscope to distinguish the smooth surface from the rough surface, which was not always visible with the naked eye. The SIS transplant was prepared so that its shape was identical to that of the corneal defect and its size was consistently 1 to 2 mm larger than the surface area of loss of substance. The transplant was then placed with its rough face directly against the surgical site. Several layers of biomaterial, depending on the depth of the defect to be filled, were laid into the corneal defect, by stacking one layer on top of the other. The multi-layered transplant was microsurgically sutured to the cornea using absorbable monofilament suture material (Vicryl, Ethicon sutures, polyglactin 910, size 9/0, Johnson & Johnson Int.). The transplant was positioned by four sutures placed at four cardinal points of the corneal defect, then completed with as many sutures as required depending on the size of the loss of substance, thereby fixing the transplant firmly to the cornea. Regular irrigation with isotonic solution was performed during the surgery to prevent any drying. A third eyelid flap (anchored to the upper eyelid) was then placed

for a period of three weeks. Oral treatment with 2 mg/kg/day marbofloxacin (Marbocyl, Vetoquinol) was prescribed for three weeks, as was twice daily application of topical gentamicin eye drops (Soligental, Virbac) placed onto the eyelid flap.

The first re-examination of cases was made by the referring veterinarian 10 days post-operatively, with the aim of confirming that the third eyelid flap was in place and that no discomfort was present. All animals were examined three weeks post-operatively by the operating surgeon when the third eyelid flap was removed and corneal healing evaluated. At 6 and 12 weeks later, the patients were re-examined and a complete ophthalmological examination (including an examination of the cornea by slit-lamp biomicroscopy and fluorescein testing) carried out.

RESULTS

Description

The 102 animals in the study included 60 dogs and 42 cats (4 of which had bilateral ocular disease) (Table 1). There were 23 breeds of dogs represented: shih-tzu (n=11), French bulldog (10), English setter (5), Pekingese (4), pug (4), boxer (3), Yorkshire terrier (3), beagle (3), Lhasa apso (2), Brittany spaniel (2), American Staffordshire terrier (1), Beauce shepherd (1), Braque d'Auvergne (1), chihuahua (1), Chinese crested dog (1), cross-breed (1), Bordeaux mastiff (1), English bulldog (1), great Dane (1), Gordon setter (1), Irish red setter (1), Japanese spaniel (1)

and Siberian husky (1). The average age was 5.4 years (ranging from 3 months to 13 years). There were 31 males of which 2 had been neutered, and 29 females of which 7 had been neutered. Four breeds of cats were represented: Chartreux (1), domestic shorthair (11), exotic shorthair (1), Persian (29). The average age was 5.8 years (from 8 months to 13 years). There were 26 males of which 18 had been neutered and 16 females of which 12 had been neutered. Four Persian cats had bilateral ocular disease (corneal sequestrum).

Clinical examination

The three corneal insults identified were traumatic (corneal injury with severe loss of substance), infectious/keratomalacic (deep melting corneal ulcer) and surgical (deep keratectomy). All 60 dogs had unilateral lesions with the loss of corneal substance resulting from a melting corneal ulcer in 42 cases (Fig 1a), severe corneal injury in 17 cases and surgical excision by deep keratectomy of epibulbar melanocytoma invading the cornea in 1 case (Fig 2a and 2b). Six dogs were receiving medical treatment for keratoconjunctivitis sicca: five of these were in the group with melting corneal ulcers and one in the group with traumatic corneal injuries. Corneal perforations were present in 16 eyes (Fig 3a) and 7 had descemetocoeles (Fig 4a). In the cats the corneal defects were the result of surgical excision by deep keratectomy of corneal sequestrum in 34 eyes (Figs 5 and 6), severe corneal injury in 5 eyes (Fig 7a) and melting ulcerative keratitis in 7 eyes (Fig 8a and 8b). Of the seven cases of melting ulcerative keratitis, five occurred in cats where there was a suspicion of herpetic keratitis.

Table 1. Clinical findings and postoperative results of SIS graft surgery on dogs and cats with corneal defects

Corneal disease and animals	No. of eyes	Presurgical observations	Average number of SIS layers	Postsurgical observations (3 weeks after surgery)	Postsurgical observations (3 months after surgery)	Postsurgical observations (>3 months after surgery)
Melting ulcer (dogs)	42	Corneal perforation (11 eyes) Descemetocoele (7) kcs treatment (5)	4.0	Additional topical treatment (5)	Discrete or transparent scar (27) Mild scar (11) Marked scar (4) Faint pigmentation (8) Mild pigmentation (5)	Discrete or transparent scar (9) Mild pigmentation (2) Pronounced pigmentation impairing vision (5)
Melting ulcerative keratitis (cats)	7	Descemetocoele (2) Suspicion of herpetic infection (5)	4.1		Discrete or transparent scar (3) Mild scar (3) Marked scar (1) Pigmentation: sequestrum Formation (1)	Corneal transparency (2) Discrete scar (1)
Severe corneal injury (dogs)	17	Corneal perforation (5) kcs treatment (1)	3.9	Additional topical treatment (1)	Discrete or transparent scar (13) Mild scar (3) Marked scar (1) Discrete pigmentation (4) Mild perilimbal pigmentation (2)	Corneal transparency (5)
Severe corneal injury (cats)	5	Corneal perforation (5)	3.6	Additional topical treatment (1)	Discrete scar (2) Mild scar (2) Marked scar (1)	Faint scar (1)
Sequestrum* (cats)	34	Corneal perforation (1)	2.9	Additional topical treatment (2)	Discrete or transparent scar (29) Mild scar (4) Marked scar (1) Pigmentation: recurrence of sequestrum (4)	Discrete or transparent scar (7) Mild scar (1) Discrete pigmentation (2)
Epibulbar melanocytoma (dog)	1	Corneal invasion	4		Marked scar (1)	Mild scar (1)

kcs Keratoconjunctivitis sicca

*Sequestrum with four bilateral cases

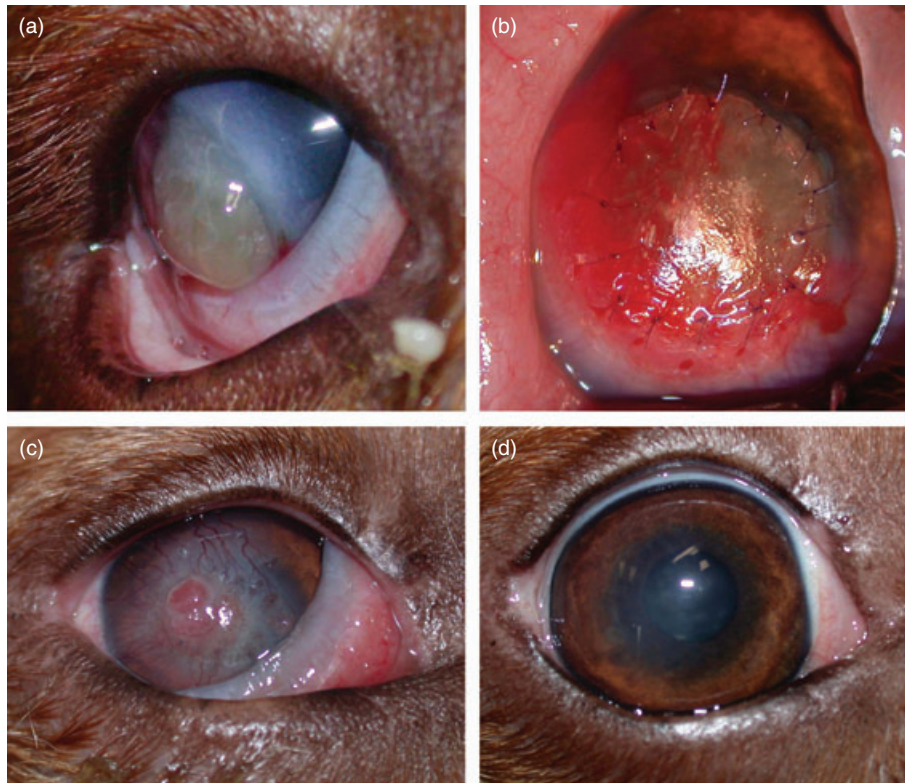


FIG 1. (a) Right eye of a two-year-old Brittany spaniel before surgery. Note the deep melting ulcer and the large descemetocoele. (b) Same dog as (a) after porcine small intestinal submucosa surgical graft and before covering with the third eyelid. (c) Same dog as (a) three weeks after surgery. Note the acceptance of the transplant well integrated into the cornea, and the intense corneal neovascularisation. (d) Same dog as (a) three months after surgery. Note that good corneal transparency resulted in restoration of vision

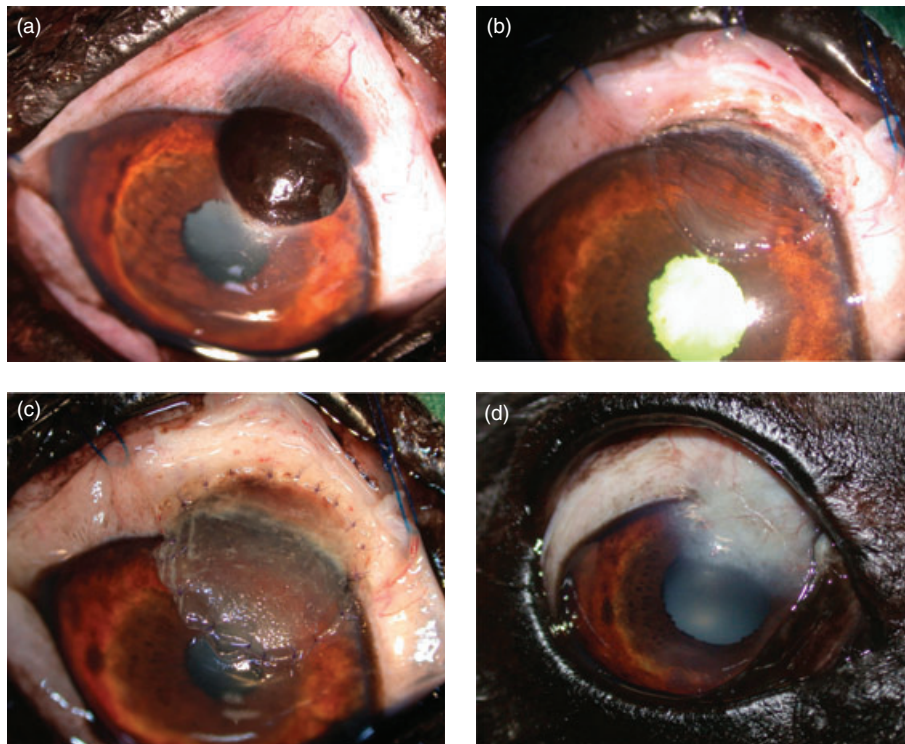


FIG 2. (a) Right eye of a 13-year-old Braque d'Auvergne. Note the epibulbar melanocytoma invading the cornea. (b) Same dog as (a) after surgical excision by deep sclerokeratectomy. (c) Same dog as (a) after SIS graft, before third eyelid flap. (d) Same dog as (a) three months after surgery. Note the marked corneal scar with mild vascularisation, not impairing the visual axis

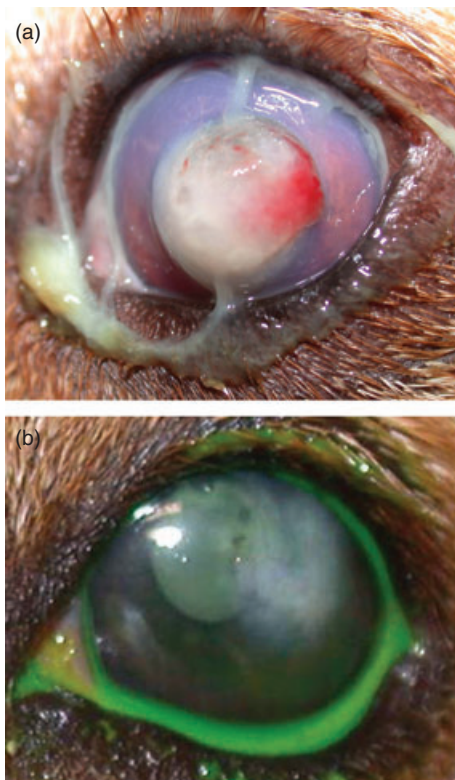

FIG 3. (a) Left eye of a four-year-old beagle. Note the melting ulcer with large iris prolapse. (b) Same dog as (a) three months after surgery. Note the mildly vascularised corneal scar

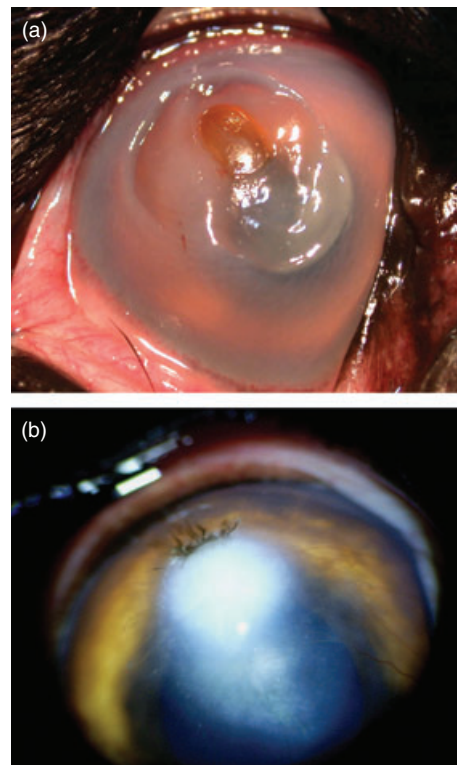


FIG 4. (a) Right eye of a two-year-old great Dane. Note the deep melting ulcer with descemetocoele. (b) Same dog as (a) three months after surgery. Note the marked corneal scar with faint pigmentation

Six eyes had perforated corneas and two had descemetocoeles (Fig 9a). The 106 eyes included in this study were all affected with a severe loss of corneal substance, i.e. the loss of at least half of the thickness of the corneal stroma, confirmed by examination with a slit-lamp biomicroscope or by an operating microscope for the 35 cases of surgically induced defect.

Treatment

The number of layers of biomaterial used was dependent on the depth of the defect to be filled. The average number of layers for the 106 cases was 3.62 (ranging from one to six layers). In the canine group, the 60 cases were treated with an average of 3.98 layers (from one to six layers), with an average of 4.02 layers for melting corneal ulcers (Fig 1b), 3.88 layers for losses of substance through injury and four layers for the only case of epibulbar melanocytoma invading the cornea (Fig 2c). In the feline group, the 46 cases were treated with an average of 3.15 layers (from one to five layers), with an average of 2.88 layers for the cases of reconstruction following surgical excision of corneal sequestrum (Figs 5d and 6b), 4.14 layers for the cases of melting ulcerative keratitis (Fig 8c) and 3.6 layers for losses of substance through injury (Fig 7b).

Outcome

On removing the third eyelid flap three weeks post-surgery, centripetal corneal neovascularisation was systematically observed, with variable intensity for each case (Figs 1c and 8d). Examination of the cornea by slit-lamp biomicroscopy followed by fluorescein

testing showed full integration of the biomaterial within the cornea, with total reconstitution of the corneal epithelium in 97 cases at the three-week assessment. Minor complications occurred in nine cases, with partial integration of the biomaterial, estimated at about 75% integration (Fig 10). These nine cases were six dogs and three cats. Two of these six dogs were receiving treatment for keratoconjunctivitis sicca, and three others had been operated on for corneal perforations. Two of the three cats were being treated for herpetic keratitis, of which one had a perforated cornea before undergoing surgery. These nine cases of partial acceptance of the transplant finally recovered completely, with total integration of the biomaterial and resultant corneal healing after additional topical treatment over a one-to-three-week period following the third eyelid flap removal. This treatment included artificial tears and antibiotics three times a day: fusidic acid (Fucithalmic Vet, Dechra Veterinary Products) or gentamicin drops (Soligental, Virbac).

A topical suspension of dexamethasone 0.1% and tobramycin 0.3% (Tobradex, Alcon) was prescribed in a majority of cases with the aim of reducing corneal neovascularisation and scarring, except for cats with suspicion of herpetic infection. These cats were those presented with deep stromal keratitis and history of signs compatible with herpetic infection (initially spontaneous superficial corneal ulcers, complicated in secondary immune-mediated stromal keratitis). Topical dexamethasone was administered approximately one to two weeks after removing the third eyelid flap, except for the nine cases of partial transplant

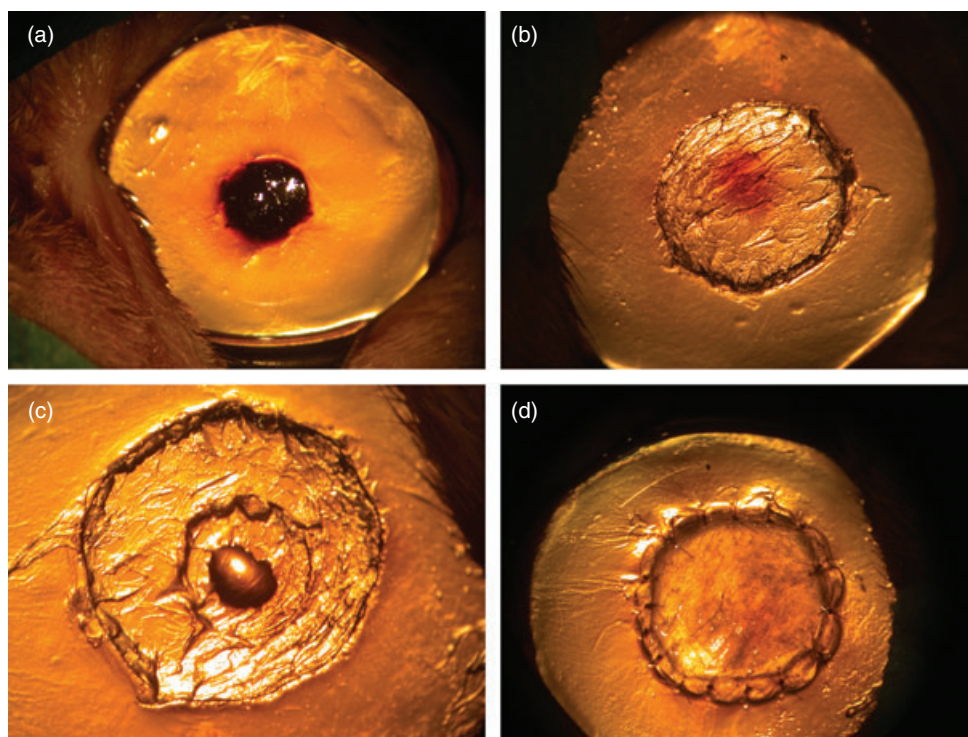


FIG 5. (a) Left eye of a five-year-old Persian cat. Note the deep corneal sequestrum. (b) Same cat as (a) after the first step of keratectomy. Note the persistence of pigmentation in the deep corneal stroma. (c) Same cat as (a) after the second step of keratectomy. Note the total resection of sequestrum and the leakage of aqueous humour (keratectomy until perforation). (d) Same cat as (a) after a porcine SIS surgical graft and before covering with the third eyelid

acceptance, for which the treatment was not started until the biomaterial was fully integrated (approximately three weeks after additional treatment). Topical dexamethasone was administered with caution, at first once a day or once every other day for approximately two weeks, then twice a day in some cases for a period depending on the intensity of scarring and corneal neovascularisation, often from one to four weeks. As for sequestrum cases, administration was only when necessary over a short period (less than a week). After 12 weeks, re-evaluation showed that corneal neovascularisation was present in 50 cases (47.2%), from discrete (34 cases, 32.1%) (Fig 3b) to mild (16 cases, 15.1%) (Figs 7c and 9b). Vision was preserved in all eyes without exception (positive menace response) at three-months post-procedure. In 74 cases (69.8%) the corneal scar was either transparent or discrete (Figs 1d, 6c and 8e), whilst in 32 cases (30.2%), a mild (23 cases, 21.7%) or marked (9 cases, 8.5%) scar (Figs 2d, 4b and 9b) was present but did not obstruct vision.

In seven canine cases (6.6%), a mild corneal pigmentation could be observed at three months, but did not impair vision. Of these seven dogs, all were brachycephalic: four were shih-tzus (including three that had perforated corneas), two were Pugs, whilst the last was a Pekingese with a perforated cornea. In five feline cases (4.7%), a mild stromal pigmentation (Fig 11) was present at the three-month check, and was diagnosed as the beginning of sequestrum formation. In two eyes, this resulted from sequestration in one Persian cat which was affected in both eyes. This cat was examined at nine months after surgery and

the pigmentation had totally disappeared in both eyes. The three other feline cases (two sequestrations, one melting ulcerative keratitis) where onset of corneal pigmentation could be observed were not followed beyond three months. In 12 other canine cases (11.3%), a faint pigmentation was present.

Thirty-four animals (36 eyes) were followed over a period longer than 12 weeks (from 4 to 11 months); major complications were encountered in five of these eyes, which became visually impaired because of pronounced pigmentation. Vision was preserved in 31 eyes (Fig 7d).

DISCUSSION

SIS is a biomaterial composed of an acellular collagen matrix that is initially invaded by fibroblasts which are then replaced by corneal stromal cells (Vanore and others 2007). In addition to collagen, this biomaterial is composed of fibronectin, hyaluronic acid, chondroitin sulphate, heparin sulphate and growth factors (Vanore and others 2007). Besides promoting the proliferation and migration of stromal cells, these growth factors, particularly TGFβs (transforming growth factor-beta), also inhibit the synthesis of metalloproteinases (Roberts and others 1990). This biomaterial therefore appears particularly indicated for the surgical treatment of melting corneal ulcers in which the corneal stroma is quickly destroyed by a process of enzymatic lysis, caused by metalloproteinase activity. Melting ulcers (also termed keratomalacia)

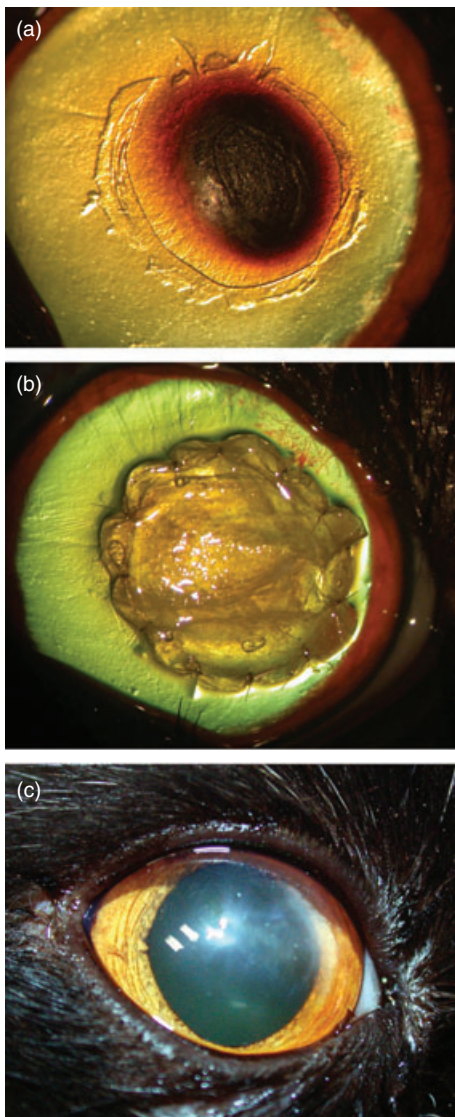


FIG 6. (a) Right eye of a fifteen-month-old Persian cat. Note the deep corneal sequestrum. (b) Same cat as (a) after a porcine SIS surgical graft and before covering with the third eyelid. (c) Same cat as (a) three months after surgery. Note the good corneal transparency resulting in restoration of vision

are characterised by gelatinisation and liquefaction of the corneal stroma, diagnosed by slit-lamp biomicroscopy. In such cases, an extensive debridement of necrotic and collagenolytic corneal tissue by keratectomy is necessary before SIS corneal grafting (Vanore and others 2007). Although SIS appears resistant to protease activity, a surrounding healthy cornea is required to support the graft material (Bussieres and others 2004). In cases with melting ulcer and severe traumatic lesions, the surgical preparation of the impaired site was performed in our series with micro-scissors to eliminate areas of lysed or devitalised stroma. Care was taken to preserve Descemet's membrane when it was visible. Regarding surgical defects (excision of sequestrum and the case of epibulbar melanocytoma invading the cornea), the keratectomy had to be continued until only healthy tissue remained at the base of the defect. In cases of corneal sequestra (Figs 5a and 6a), particular

care was taken when performing the deep keratectomy, to eliminate the deep stromal brown pigmented tissue often visible after excision of the sequestrum (Fig 5b). In some cases keratectomy until perforation was required to ensure full excision of the sequestrum (Fig 5c). No samples for bacterial culture or cytology were collected in our series but topical gentamicin was used after surgery in all cases.

Previous studies have reported the use of soft bandage contact lenses (Featherstone and others 2001) and conjunctival graft (Lewin 1999, Bussieres and others 2004) in association with a SIS graft, but the use of a bandage contact lens can sometimes lead to the loss of the implanted material in lively patients (Whitley and Gilger 1999). Conjunctival transplants may have the disadvantage of being opaque and impeding vision. Other grafting procedures such as corneoconjunctival or corneoscleral transposition may be used to decrease corneal scarring and allow a clearer post-operative cornea than that seen after conjunctival corneal graft (Gilger and Whitley 1999). However, these grafting procedures damage normal and healthy corneal tissue (Gilger and Whitley 1999) and they are time-consuming techniques (Hendrix 2007). Furthermore, they are not indicated in cases of melting ulcer, inasmuch as sufficient peripheral healthy cornea is needed for these grafting procedures (Gilger and Whitley 1999).

In the current series, following the SIS graft, a third eyelid flap was placed for a period of three weeks. The use of a third eyelid flap may be considered inappropriate for severe corneal disease. These flaps do obscure visualisation of the cornea, inhibit topical medications from reaching the cornea and they do not deliver an appropriate blood supply (Hendrix 2007). However, in two previous cases which treated before this series (one French Bulldog with melting ulcer and one Persian cat with sequestrum), the author had performed SIS grafting without a third eyelid flap protection, and observed significant desiccation of the transplant followed by graft failure. Therefore, it is proposed that the eyelid flap may help protect the biomaterial by keeping it hydrated, even if it prevents visualisation of the progress of the implant. Furthermore, the third eyelid flap has been used successfully in conjunction with frozen lamellar corneal grafts for two weeks after surgery, even in cases of melting ulcers, with the aim of protecting the graft from blinking movements and to help maintain pressure on the graft's surface (Hansen and Guandalini 1999). In another report on seven cases with deep melting ulcers treated by surgical debridement and SIS grafting, a third eyelid flap was placed for a two-week period in six of seven cases to protect the SIS graft after surgery, and no complications occurred (Vanore and others 2007).

The period of three weeks before removing the third eyelid flap is one week longer than in the series by Vanore. The current author preferred to keep the implant protected under the eyelid flap for a further week, especially in severe cases (corneal perforation following trauma or keratomalacia). This period of three weeks may seem a long time for a severe corneal disease with potential post-operative complications, but the study of Vanore reported no complications in six cases with melting corneal ulcers treated surgically with surgical debridement, SIS grafting, and third eyelid flap placement (Vanore and others 2007). In the

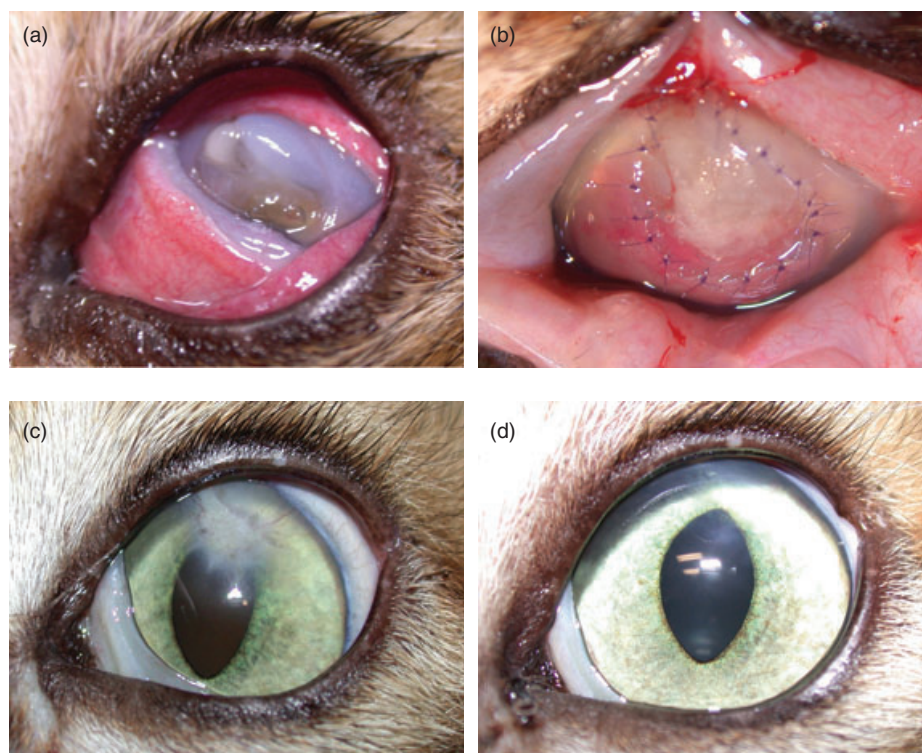

FIG 7. (a) Left eye of a six-year-old domestic shorthair cat. Note the severe traumatic corneal defect. (b) Same cat as (a) after porcine SIS graft. (c) Same cat as (a) three months after surgery. Note the marked corneal scar with mild vascular response. (d) Same cat as (a) seven months after surgery. Note the faint scar

current series, only nine cases exhibited minor healing complications (partial integration of the biomaterial).

A topical suspension of dexamethasone was cautiously administered in most cases to reduce corneal neovascularisation and scarring, except for cats with suspicion of herpetic infection. These cats were those with deep stromal keratitis and history of signs compatible with herpetic infection (initially spontaneous superficial corneal ulcers, complicated in secondary immune-mediated stromal keratitis). The administration was very careful, at first once a day or once every other day for approximately two weeks, then twice a day for some cases, for a period depending on the intensity of scarring and corneal neovascularisation. The use of topical corticosteroids three times a day for six weeks after lamellar keratoplasty was recommended in a series of four Persian cats (six eyes) with corneal sequestra to lessen the probability of corneal vascularisation and subsequent graft rejection (Pena Gimenez and Morales Farina 1998). However, cats treated with topical corticosteroids may be at risk of developing corneal ulcers from activation of latent herpesvirus, inasmuch as up to 50% of clinically normal cats have FHV1-DNA in the cornea (Stiles and others 1997, Townsend and others 2004). Despite the temptation to use topical steroids to keep the cornea clear, topical corticosteroids must be very cautiously administered and their use delayed if possible (Hansen and Guandalini 1999), as in this series. Recrudescence of any FHV-1-associated disease in this series was not encountered, except in five cases for which marked or faint stromal pigmentation was present at the three-month check, that is to say recurrence of sequestrum.

The use of topical corticoids is normally contraindicated in cases of melting ulcers, because they increase the proteolytic activity of corneal collagenase. However in the current series, keratomalacia was totally resolved in every case of melting ulcer (total integration of SIS and corneal healing), when topical dexamethasone was commenced.

A faint to mild pigmentation without vision impairment was observed at the three-month post-procedure examination in 22.6% of cases. Some of these cases had corneal pigmentation before surgery, and similar findings were described in a study describing the use of frozen lamellar corneal grafts (Hansen and Guandalini 1999). In our series, only 36 eyes were followed over a period longer than 3 months (from 4 to 11 months), among them five became visually impaired because of pronounced pigmentation. These five cases were all brachycephalic dogs with melting ulcers, which initially had very severe corneal lesions (perforation or descemetocoele) and presented with corneal pigmentation before surgery. In brachycephalic breeds, the pigmentary keratitis syndrome is one of the disorders in which corneal pigmentation occurs (Gilger 2007). In these breeds, chronic exposure (because of prominent eyes with large palpebral fissures, also known as euryblepharon) causes chronic corneal irritation, resulting in corneal pigmentation due to migration of melanocytic cells from the limbal and perilimbal tissues (Whitley and Gilger 1999). Melanin pigment within macrophages and fibroblasts may also develop (Whitley and Gilger 1999). In our series, it seems that brachycephalic dogs with pigmentary keratitis syndrome and initially pigmented cornea may be

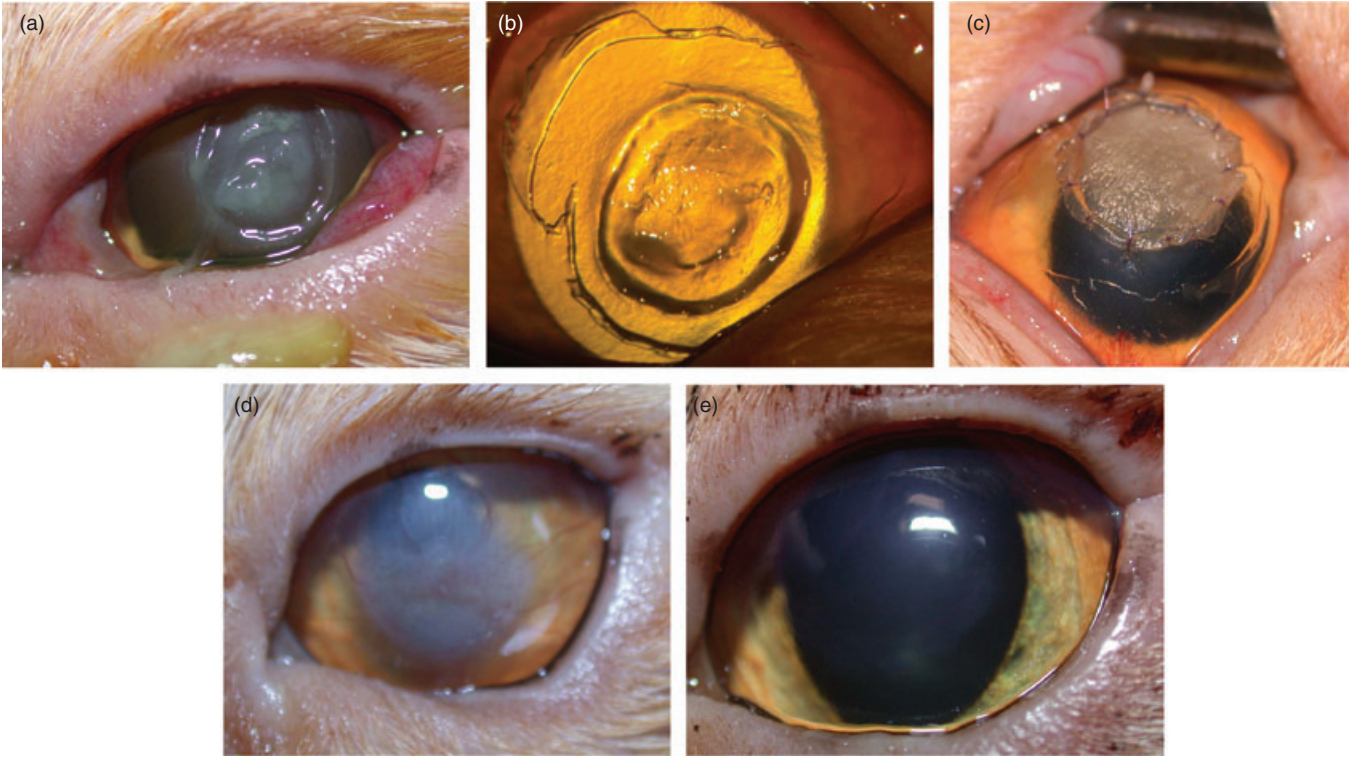


FIG 8. (a) Left eye of a seven-year-old Persian cat. Note the melting ulcerative keratitis. (b) Same cat as (a) before grafting. Note the deep melting ulcer. (c) Same cat as (a) after a porcine SIS surgical graft and before covering with the third eyelid. (d) Same cat as (a) three weeks after surgery. Note the acceptance of the transplant which has integrated into the cornea, and the slight corneal neovascularisation. (e) Same cat as (a) three months after surgery. Note the good corneal transparency

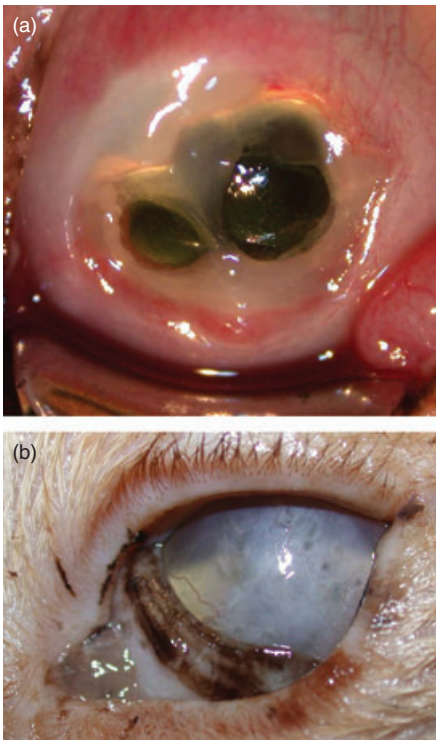


FIG 9. (a) Left eye of a eight-year-old domestic shorthair cat. Note the deep melting ulcer with a large descemetocoele. (b) Same cat as (a) three months after surgery. Note the marked corneal scar with mild vascular response

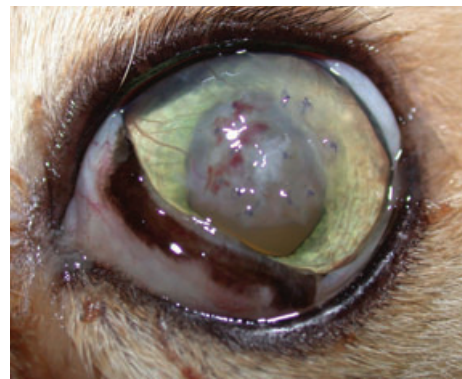


FIG 10. Left eye of a five-year-old Persian cat three weeks after surgery. Note the partial integration of the biomaterial

predisposed to a worsening of the pigmentation after grafting surgery, especially in cases of severe corneal lesions (descemetocoele or perforation).

In summary, this large retrospective study presenting data from a larger number of cases than previously published shows that SIS is a very efficient biomaterial for use in corneal reconstruction surgery. Furthermore, this grafting technique allows preservation of vision by restoring corneal transparency in the vast majority of cases. However, brachycephalic dogs with initially pigmented cornea and severe corneal defect may be predisposed to a worsening of the pigmentation after grafting surgery.

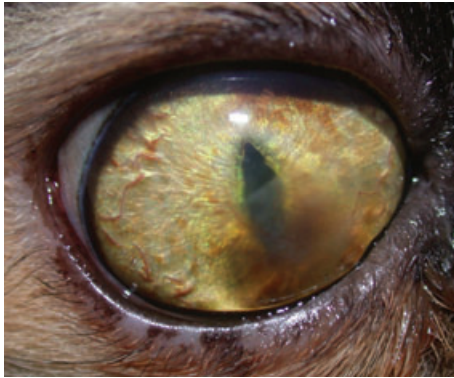


FIG 11. Right eye of a four-year-old Persian cat three months after surgery. Note the sequesterum reformation and the mild vascularisation

Conflict of interest

None of the authors of this article has a financial or personal relationship with other people or organisations that could inappropriately influence or bias the content of the paper.

References

AIKEN, S. W., BADYLAK, S. F., TOOMBS, J. P., SHELBORNE, K. D., HILES, M. C., LANTZ, G. C. & VAN SICKLE, D. (1994) Small intestinal submucosa as an intra-articular ligamentous graft material: a pilot study in dogs. *Veterinary and Comparative Orthopaedics and Traumatology* **7**, 124-128

ANDRADE, A. L., LAUS, J. L., FIGUEIREDO, F. & BATISTA, C. M. (1999) The use of preserved equine renal capsule to repair lamellar corneal lesions in normal dogs. *Veterinary Ophthalmology* **2**, 79-82

BADYLAK, S. F., LANTZ, G. C., COFFEY, A. & GEDDES, L. A. (1989) Small intestinal submucosa as a large diameter vascular graft in the dog. *Journal of Surgical Research* **47**, 74-80

BARROS, P. S. M., SAFATLE, A. M. V., MALERBA, T. A. & BURNIER JUNIOR, M. (1995) The surgical repair of the cornea of the dog using pericardium as a keratoprosthesis. *Brazilian Journal of Veterinary Research and Animal Science* **32**, 251-255

BARROS, P. S. M., SAFATLE, A. M. V. & RIGUEIRO, M. (1997) Use of horse pericardium preserved in glycerin as corneal graft in dogs. Experimental study. *Brazilian Journal of Veterinary Research and Animal Science* **34**, 138-141

BARROS, P. S. M., GARCIA, J. A., LAUS, J. L., FERREIRA, A. L. & SALLES GOMES, T. L. (1998) The use of xenologous amniotic membrane to repair canine corneal perforation created by penetrating keratectomy. *Veterinary Ophthalmology* **1**, 119-123

BARROS, P. S. M., SAFATLE, A. M. V., GODOY, C. A., SOUZA, M. S. B., BARROS, L. F. M. & BROOKS, D. E. (2005) Amniotic membrane transplantation for the reconstruction of the ocular surface in three cases. *Veterinary Ophthalmology* **8**, 189-192

BUSSIERES, M., KROHNE, S. G., STILES, J. & TOWNSEND, W. M. (2004) The use of porcine small intestinal submucosa for the repair of full-thickness corneal defects in dogs, cats and horses. *Veterinary Ophthalmology* **7**, 352-359

COBB, M. A., BADYLAK, S. F., JANAS, W., SIMMONS-BYRD, A. & BOOP, F. A. (1999) Porcine small intestinal submucosa as a dural substitute. *Surgical Neurology* **51**, 99-104

DEJARDIN, L. M., ARNOCKY, S. P. & CLARKE, R. B. (1999) Use of small intestinal submucosal implants for regeneration of large fascial defects: an experimental study in dogs. *Journal of Biomedical Materials Research* **46**, 203-211

FEATHERSTONE, H. J. & SANSOM, J. (2000) Intestinal submucosal repair in two cases of feline ulcerative keratitis. *Veterinary Record* **146**, 136-138

FEATHERSTONE, H. J. & SANSOM, J. (2004) Feline cornea sequestra: a review of 64 cases (80 eyes) from 1993 to 2000. *Veterinary Ophthalmology* **7**, 213-227

FEATHERSTONE, H. J., SANSOM, J. & HEINRICH, C. L. (2001) The use of porcine small intestinal submucosa in ten cases of feline corneal disease. *Veterinary Ophthalmology* **4**, 147-153

GELATT, K. N. & GELATT, J. P. (1995) Handbook of Small Animal Ophthalmic Surgery, Vol 2: Corneal and Intraocular Procedures. New York, NY, USA: Pergamon

GELATT, K. N. & GELATT, J. P. (2003) Small Animal Ophthalmic Surgery, Practical Techniques for the Veterinarian. Edinburgh: Elsevier Science Limited (657 DANS LE TEXTE)

GILGER, B. C. (2007) Diseases and surgery of the canine cornea and sclera. In: *Veterinary Ophthalmology* 4th edn. Ed K. N. Gelatt. Blackwell Publishing, Ames, Iowa, USA. pp 690-752

GILGER, B. C. & WHITLEY, R. D. (1999) Surgery of the cornea and sclera. In: *Veterinary Ophthalmology* 3rd edn. Ed K. N. Gelatt. Lippincott, Williams & Wilkins, Baltimore, Maryland, USA. pp 675-700

GRIGUER, F., RAYMOND, I. & REGNIER, A. (2001) Preliminary evaluation of the biocompatibility of the small intestinal submucosa (SIS) in rabbit cornea. *Revue Medicale Veterinaire* **152**, 597-604

HAKANSON, N. E. & MERIDETH, R. E. (1987) Conjunctival pedicle grafting in the treatment of corneal ulcers in the dog and cat. *Journal of the American Animal Hospital Association* **23**, 641-648

HANSEN, P. A. & GUANDALINI, A. (1999) A retrospective study of thirty cases of frozen lamellar corneal graft in dogs and cats. *Veterinary Ophthalmology* **2**, 233-241

HENDRIX, D. V. H. (2007) Canine conjunctiva and nictitating membrane. In: *Veterinary Ophthalmology*. 4th edn. Ed K. N. Gelatt. Blackwell Publishing, Ames, Iowa, USA. pp 662-689

LASSALINE, M. E., BROOKS, D. E., OLLIVIER, F. J., KOMAROMY, A. M., KALLBERG, M. E. & GELATT, K. N. (2005) Equine amniotic membrane transplantation for corneal ulceration and keratomalacia in three horses. *Veterinary Ophthalmology* **8**, 311-317

LEWIN, G. A. (1999) Repair of a full thickness corneoscleral defect in a German shepherd dog using porcine small intestinal submucosa. *Journal of Small Animal Practice* **40**, 340-342

OLLIVIER, F. J., KALLBERG, M. E., PLUMMER, C. E., BARRIE, K. P., O'REILLY, S., TAYLOR, D. P., GELATT, K. N. & BROOKS, D. E. (2006) Amniotic membrane transplantation for corneal surface reconstruction after excision of corneolimbic squamous cell carcinomas in nine horses. *Veterinary Ophthalmology* **9**, 404-413

PENA GIMENEZ, T. & MORALES FARINA, I. (1998) Lamellar keratoplasty for the treatment of feline corneal sequestrum. *Veterinary Ophthalmology* **1**, 163-166

ROBERTS, A. B., HEINE, U. I., FLANDERS, K. C. & SPORN, M. B. (1990) Transforming growth factor-beta. Major role in regulation of extracellular matrix. *Annals of the New York Academy of Sciences* **580**, 225-232

STILES, J., MCDERMOTT, M., BIGSBY, D., WILLIS, M., MARTIN, C., ROBERTS, W., GREENE, C. (1997) Use of nested polymerase chain reaction to identify feline herpesvirus in ocular tissue from clinically normal cats and cats with corneal sequestra or conjunctivitis. *American Journal of Veterinary Research* **58**, 338-342

TOWNSEND, W. M., STILES, J., GUPTILL-YORAN, L., KROHNE, S.G. (2004) Development of a reverse transcriptase-polymerase chain reaction assay to detect feline herpesvirus-1 latency associated transcripts in the trigeminal ganglia and corneas of cats that did not have clinical signs of ocular disease. *American Journal of Veterinary Research* **65**, 314-319

VANORE, M., CHAHORY, S., PAYEN, G. & CLERC, B. (2007) Surgical repair of deep melting ulcers with porcine small intestinal submucosa (SIS) graft in dogs and cats. *Veterinary Ophthalmology* **10**, 93-99

WHITLEY, R. D. & GILGER, B. C. (1999) Diseases of the canine cornea and sclera. In: *Veterinary Ophthalmology*. 3rd edn. Ed K. N. Gelatt. Lippincott, Williams & Wilkins, Baltimore, Maryland, USA. pp 635-673

WILKIE, D. A. & DAN WOLF, E. (1991) Treatment of epibulbar melanocytoma in a dog, using full-thickness eyewall resection and synthetic graft. *Journal of American Veterinary Medical Association* **198**, 1019-1022